



Case Report Uveitis

Multiple evanescent white dot syndrome following COVID-19 infection: A case report

Fatemeh Abdi¹, Sara Hemmati¹, Masoume Sharafinejad¹, Arzhang Gordiz¹, Seyyed Saeed Aghili¹, Vahid Zare Hosseinabadi¹

¹Department of Ophthalmology, Iran University of Medical Sciences, Tehran, Iran.



*Corresponding author:

Sara Hemmati,
Department of Ophthalmology,
Iran University of Medical
Sciences, Tehran, Iran.

hemmati1373@yahoo.com

Received: 05 July 2023

Accepted: 18 November 2023

Published: 30 December 2023

DOI

10.25259/LAJO_13_2023

Quick Response Code:



ABSTRACT

Multiple evanescent white dot syndrome (MEWDS) is typically a unilateral and transient condition without an exact known underlying cause. Its pathogenesis may involve an immune response to viral antigens that have gained access to the retinal receptor cells. It has been hypothesized that the COVID-19 virus can activate some autoimmune responses. Here, we report a case of MEWDS in a 16-year-old girl with a history of COVID-19 infection two weeks before the visual symptoms. The symptoms and signs improved without any treatment after a three-month follow-up period. In our case, MEWDS occurred shortly after COVID-19 infection and resolved without treatment in three months. Considering ophthalmologic and immunologic associations of COVID-19 can help ophthalmologists in the diagnosis and treatment of similar disorders in the COVID-19 era.

Keywords: Multiple evanescent white dot syndrome, COVID-19, Coronavirus

INTRODUCTION

The World Health Organization declared that coronavirus 2019 infection (COVID-19) has led to a pandemic in March 2020.^[1] COVID-19 is a complex disease which can affect many parts of the human body.^[2] Ophthalmologic symptoms and signs are reported to be the presenting and even only manifestations of this disorder.^[3]

Multiple evanescent white dot syndrome (MEWDS) is typically a unilateral syndrome which usually occurs acutely and manifests with transient small dots at the level of the outer retina and retinal pigment epithelium and foveal granularity. Other signs may include optic nerve head edema, mild anterior chamber reaction, and vitritis.^[4] In about one-third of patients, a viral illness occurs before the onset of the disease.^[5]

The underlying pathogenesis of MEWDS is not exactly clear, but it may involve an immune response to viral antigens that have gained access to the retinal receptor cells.^[4,5] It has been hypothesized that the COVID-19 virus can activate some autoimmune responses.^[6]

Here, we report a case of MEWDS that occurred following COVID-19 infection.

CASE REPORT

A 16-year-old girl came to our clinic with a chief complaint of blurred vision in her left eye. Her past medical history included a COVID-19 infection two weeks before the onset of her visual

This is an open-access article distributed under the terms of the Creative Commons Attribution-Non Commercial-Share Alike 4.0 License, which allows others to remix, transform, and build upon the work non-commercially, as long as the author is credited and the new creations are licensed under the identical terms.

©2023 Published by Scientific Scholar on behalf of Latin American Journal of Ophthalmology

symptoms. No other medical history or family history was mentioned. On examination, the best corrected visual acuity (BCVA) was ten out of ten in her right eye and five out of ten in her left eye. There was no afferent pupillary defect, and intraocular pressure was within normal limits in both

eyes. In the anterior segment examination, no pathological finding was detected, and there was no anterior chamber reaction in either eye. As shown in Figure 1a-c, fundus photograph [Figure 1a], fundus autofluorescence (FAF) [Figure 1b] and macular optical coherence tomography [Figure 1b] and macular optical coherence tomography

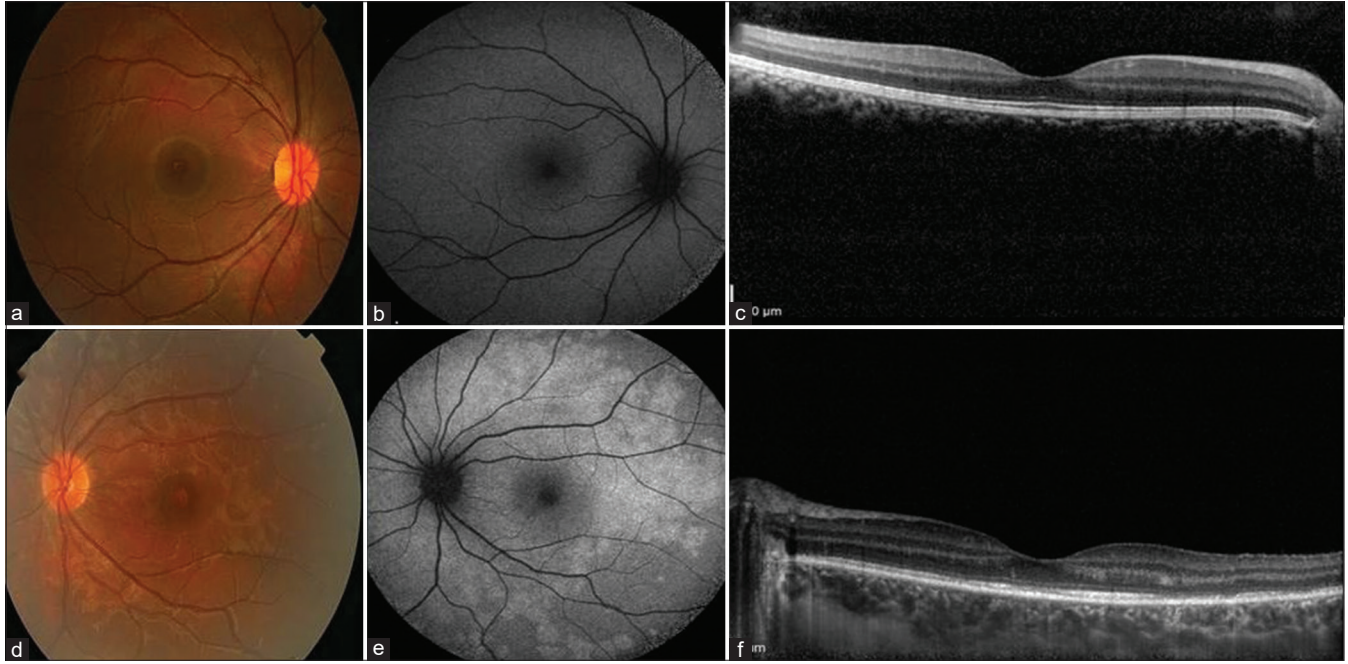


Figure 1: Imaging of both eyes at the time of presentation. (a) Fundus photograph, (b) fundus autofluorescence (FAF), and (c) macular optical coherence tomography (OCT) of the right eye is normal. (d) Fundus photograph of the left eye shows subtle deep, yellow lesions in the retina and foveal granularity. (e) FAF of the left eye demonstrates a ring of circumpapillary hyperautofluorescence and surrounding scattered small foci of hyperautofluorescence. (f) OCT of the left eye shows attenuation of the ellipsoid and interdigitations zones.

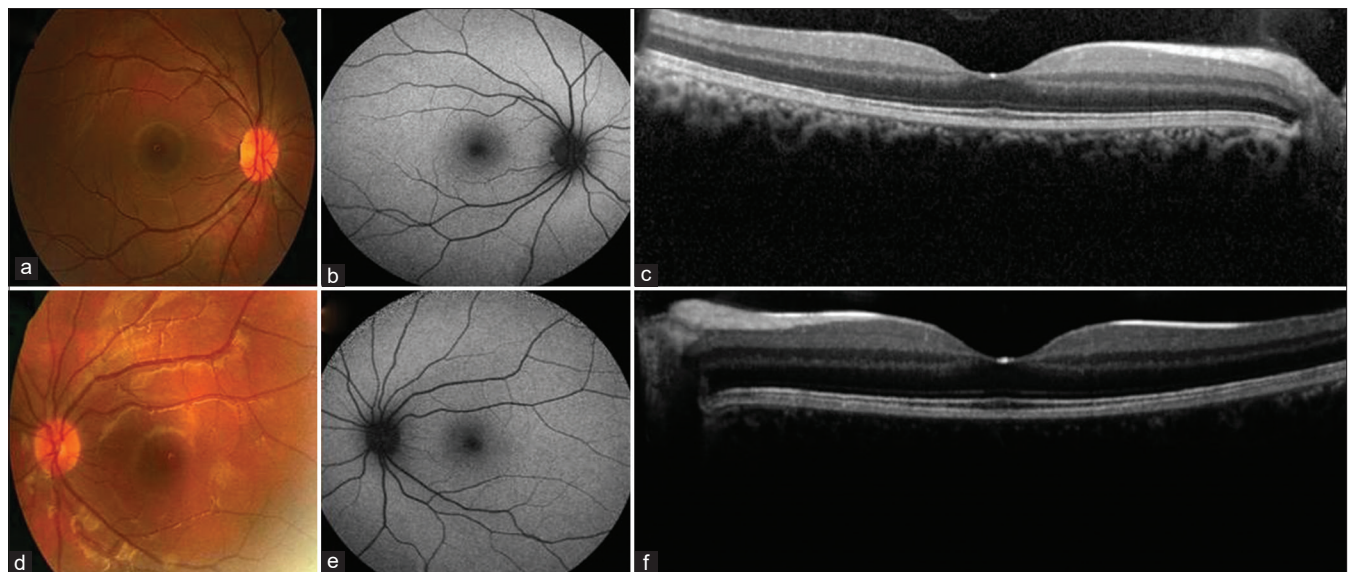


Figure 2: Imaging of both eyes at the three-month follow-up. (a) Fundus photograph, (b) fundus autofluorescence (FAF), and (c) macular optical coherence tomography (OCT) of the right eye is normal. (d) In the fundus photograph of the left eye, there is a decrease in the number and prominence of the deep retinal yellow lesions. (e) FAF of the left eye is nearly normal. (f) Macular OCT of the left eye shows reconstitution and recovery of the ellipsoid zone.

(OCT) [Figure 1c] of the right eye is normal at the time of presentation. On the other side, fundoscopic examination of the left eye revealed diffuse, subtle, deep, yellow lesions in the retina with a typical foveal granularity [Figure 1d]. Moreover, fundus autofluorescence (FAF) revealed multiple hyperautofluorescent patches throughout the macula and mid-peripheral retina [Figure 1e] and Optical coherence tomography (OCT) demonstrated attenuation of the ellipsoid and interdigitation zones in the left eye [Figure 1f]. Based on these findings, the patient was diagnosed with MEWDS, and follow-up was recommended. According to Figure 2a-c, fundus photograph [Figure 2a], FAF [Figure 2b] and macular optical coherence tomography (OCT) [Figure 2c] of the right eye is normal at the three-month follow-up. The patient also reported improved vision in her left eye and BCVA improved to 10 out of 10 after the same duration of time. Fundus examination showed a decrease in the prominence and number of the deep retinal yellow lesions during three months [Figure 2d]. Besides, FAF showed fading of the hyper-fluorescence patches at this point [Figure 2e] and OCT demonstrated reconstitution of the ellipsoid zone [Figure 2f].

DISCUSSION

MEWDS is an idiopathic disorder without an exact known pathogenesis.^[7] An immune response to viral antigens that have gained access to the retinal receptor cells could have a role in the pathogenesis of this disorder.^[7] It is hypothesized that the COVID-19 virus can activate some autoimmune responses.^[6] Suggestive clues include the increased prevalence of autoantibodies in patients with this infection and also the susceptibility of patients with autoimmune disorders to COVID-19 infection.^[6] It has also been proposed that a phase of autoimmunity can occur following COVID-19 infection.^[7]

A few cases of MEWDS following COVID-19 infection are reported in the literature. Jain *et al.* reported a 17-year-old boy with MEWDS about two months after SARS-CoV-2 infection, which responded well to oral corticosteroids.^[7] There is also a case report describing an atypical case of MEWDS following COVID-19 infection in which there was no classic hypocyanelescent lesion in indocyanine green angiography (ICGA), and instead, multiple hypercyanescent lesions were noted.^[8] Furthermore, Conrady *et al.* reported a case with acute outer retinopathy similar to MEWDS but without complete recovery of vision.^[9]

On the other hand, Azar *et al.* reported that although MEWDS is possibly associated with inflammation and immunity, the incidence of MEWDS did not show a rise during the COVID-19 pandemic in their center.^[10]

CONCLUSION

In our case, MEWDS occurred shortly after COVID-19 infection and resolved without treatment in three months. Considering ophthalmologic and immunologic associations of COVID-19 can help ophthalmologists in the diagnosis and treatment of similar disorders in the COVID-19 era.

Ethical approval

The study was approved by the Institutional Ethical Committee at Iran University of Medical Sciences as a case report.

Declaration of patient consent

The authors certify that they have obtained all appropriate patient consent.

Financial support and sponsorship

Nil.

Conflicts of interest

There are no conflicts of interest.

Use of artificial intelligence (AI)-assisted technology for manuscript preparation

The authors confirm that there was no use of artificial intelligence (AI)-assisted technology for assisting in the writing or editing of the manuscript and no images were manipulated using AI.

REFERENCES

1. Cucinotta D, Vanelli M. WHO declares COVID-19 a pandemic. *Acta Biomed* 2020;91:157-60.
2. Roberts CM, Levi M, McKee M, Schilling R, Lim WS, Grocott MP. COVID-19: A complex multisystem disorder. *Br J Anaesth* 2020;125:238-42.
3. Sen M, Honavar SG, Sharma N, Sachdev MS. COVID-19 and eye: A review of ophthalmic manifestations of COVID-19. *Indian J Ophthalmol* 2021;69:488-509.
4. Tavallali A, Yannuzzi LA. MEWDS, common cold of the retina. *J Ophthalmic Vis Res* 2017;12:132-4.
5. dell'Omo R, Pavesio CE. Multiple evanescent white dot syndrome (MEWDS). *Int Ophthalmol Clin* 2012;52:221-8.
6. Providência J, Fonseca C, Henriques F, Proença R. Serpiginous choroiditis presenting after SARS-CoV-2 infection: A new immunological trigger? *Eur J Ophthalmol* 2022;32: NP97-101.
7. Jain A, Shilpa IN, Biswas J. Multiple evanescent white dot syndrome following SARS-CoV-2 infection - a case report.

- Indian J Ophthalmol 2022;70:1418-20.
8. De Salvo G, Meduri A, Vaz-Pereira S, Spencer D. An uncommon cold of the retina. *Surv Ophthalmol* 2022;67:1553-8.
 9. Conrady CD, Faia LJ, Gregg KS, Rao RC. Coronavirus-19-associated retinopathy. *Ocul Immunol Inflamm* 2021;29:675-6.
 10. Azar G, Bonnin S, Vasseur V, Faure C, Salviat F, Clermont CV,

et al. Did the COVID-19 pandemic increase the incidence of acute macular neuroretinopathy? *J Clin Med* 2021;10:5038.

How to cite this article: Abdi F, Hemmati S, Sharafinejad M, Gordiz A, Aghili S, Zare Hosseinabadi V. Multiple evanescent white dot syndrome following COVID-19 infection: A case report. *Lat Am J Ophthalmol.* 2023;6:18. doi: 10.25259/LAJO_13_2023