



Case Report Cornea

## Recurrence of keratoconus in corneal graft

Francisco Lucero Saá<sup>1</sup>, Federico Andrés Cremona<sup>1</sup>, Pablo Chiaradia<sup>1</sup>

<sup>1</sup>Department of Ophthalmology, Hospital de Clínicas José de San Martín, Buenos Aires, Argentina.



**\*Corresponding author:**

Francisco Lucero Saá,  
Department of Ophthalmology,  
Hospital de Clínicas José de  
San Martín, Buenos Aires,  
Argentina.

franlucerosaa@gmail.com

Received : 23 March 2023

Accepted : 20 May 2023

Published : 14 June 2023

**DOI**

10.25259/LAJO\_8\_2023

**Quick Response Code:**



### ABSTRACT

Keratoconus (KC) is a bilateral sight threatening disease that affects the cornea. It consists of a gradual steepening of the central cornea associated with irregular astigmatism and may lead to corneal opacities. In some cases, a keratoplasty is needed to restore vision. Even though it is not frequent, recurrence of KC in donor tissue has been described, and is usually bilateral. Recurrence may respond to problems related to the corneal graft or to personal and environmental factors that persist after surgery. We present a case of a recurrent KC 20 years after a keratoplasty with clinical, topographic, and histopathological analysis.

**Keywords:** Cornea, Ectasia, Keratoconus, Recurrent keratoconus, Keratoplasty

### INTRODUCTION

Keratoconus (KC) is a bilateral, non-inflammatory, and ectatic disorder of the cornea, caused by a thinning of the stroma that is not associated with neovascularization. The disease leads to a progressive protrusion of the central cornea, usually accompanied by irregular myopic astigmatism. The pathogenesis of KC is not fully understood, although it might be related to an alteration in glycosaminoglycans and collagen biosynthesis or to an augmented degradation of extracellular matrix by keratocytes. Genetic, environmental factors, and eye rubbing could play a role in the pathogenesis as well. Most frequently, it manifests in adolescents and young adults. In advanced cases, due to severe irregular astigmatism or scars which may diminish visual acuity dramatically, a penetrating keratoplasty (PK) or deep anterior lamellar keratoplasty may be needed. On average, the time it takes for the ectasia to recur after PK is 20 years and is usually bilateral.<sup>[1]</sup> Even though recurrence of the disease in the corneal graft is rare, it has been known to occur.<sup>[2-4]</sup> On the other hand, progression of KC in the host cornea has been reported and consists of a thinning of the recipient stroma at the graft–host junction that is visible on slit-lamp biomicroscopy. It may result on late onset post-keratoplasty astigmatism and is considered as an early sign of recurrence. In some cases, a re-raft is needed to restore vision and histopathologic analysis may evidence keratoconic findings that confirm the recurrence in donor tissue.<sup>[5,6]</sup>

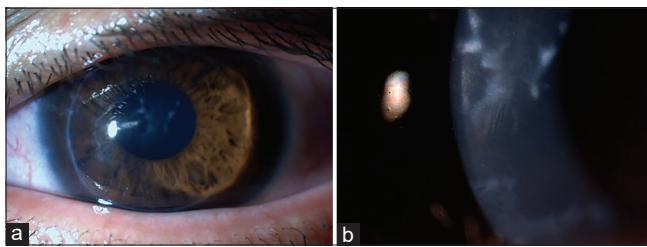
### CASE REPORT

A 40-year-old male was referred to the Cornea Service at Hospital de Clinicas in Buenos Aires. He had undergone successful bilateral corneal transplantation for KC 20 years ago and claimed that his eyesight had deteriorated in the past few years. He presented with a corrected visual acuity of 20/200 in his right eye and 20/400 in his left eye. Slit-lamp biomicroscopy

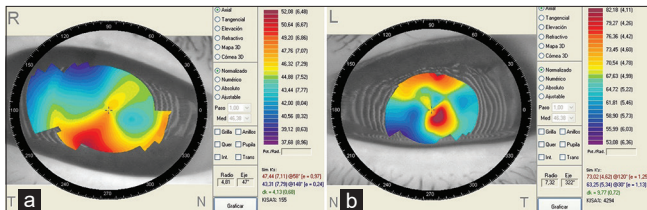
This is an open-access article distributed under the terms of the Creative Commons Attribution-Non Commercial-Share Alike 4.0 License, which allows others to remix, transform, and build upon the work non-commercially, as long as the author is credited and the new creations are licensed under the identical terms.

©2023 Published by Scientific Scholar on behalf of Latin American Journal of Ophthalmology

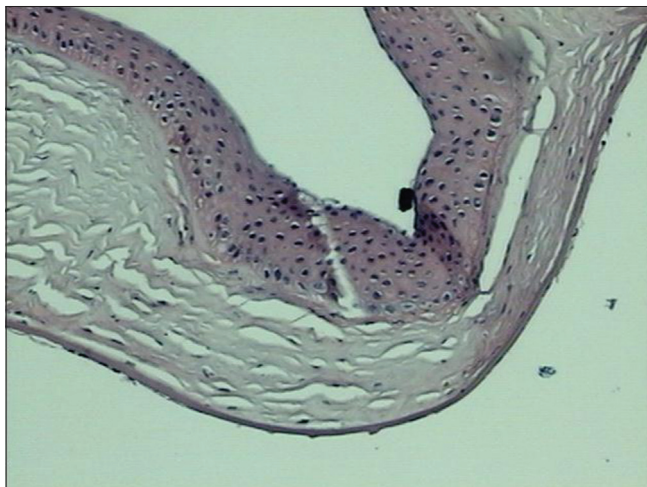
showed a postinfectious leukoma in his right eye and an ectasia with Vogt striae in his left eye [Figure 1a and b]. Corneal topography showed irregular astigmatism in his right eye with keratometric readings of 47.44D × 58° and 43.31D × 148° (kMax 52.08D); and an ectatic profile in his left eye with keratometric readings of 73.02D × 120° and 63.25D × 30° (kMax 82.18D) [Figure 2a and b]. Due to the severe compromise of visual acuity, a corneal transplant was performed in the ectatic eye. Histopathology of the corneal button revealed thinning of central epithelium and stroma, multiple breaks in Bowman's layer and interstitial edema; all features of KC [Figure 3]. One year later, topography of his right eye showed corneal steepening with keratometric



**Figure 1:** (a and b) Left eye. Slit-lamp. Keratoplasty showing an ectatic graft with central thinning, anterior scarring and Vogt striae.



**Figure 2:** (a) Corneal topography showed irregular astigmatism in the right. (b) Corneal topography showed an ectatic profile in the left eye.

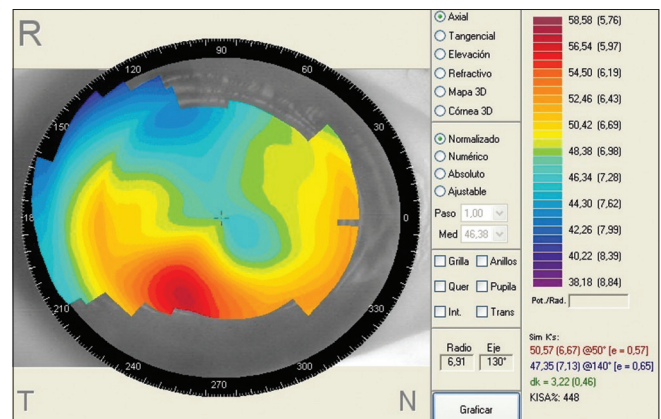


**Figure 3:** Histopathology showed thinning of central epithelium and stroma, multiple breaks in Bowman's layer, and interstitial edema.

readings of 50.57D × 50° and 47.35D × 140° (kMax 58.58D) [Figure 4], that might be interpreted as the early signs of a recurrence.

## DISCUSSION

Our patient presented with diminished visual acuity 20 years after a successful PK for KC. Slit-lamp biomicroscopy showed classic signs of KC such as central thinning, anterior stromal scarring, and Vogt striae. He underwent a PK and histopathology revealed keratoconic changes in the corneal button. Even though recurrence of KC in a corneal graft is considered to be rare, a study reported a rate of 11.7% 25 years after surgery.<sup>[7]</sup> In 1980, Abelson *et al.* were the first to describe a case of recurrent KC confirmed by histopathology.<sup>[2]</sup> A second case was reported 3 years later by Nirankari *et al.*<sup>[8]</sup> Larger case series were reported afterwards.<sup>[2,4,6]</sup> Interestingly, our patient presented with Vogt striae, a feature that only a few of the reported cases describe. The pathophysiology of the recurrence has not been fully understood yet. As the first cases to be described were unilateral, the presence of KC in the donor tissue had been proposed. Kremer *et al.* described a case of a 42-year-old patient that developed clinical and histopathological signs of recurrent KC, 7 years after the corneal transplant was performed. They ruled out a misdiagnosed KC in donor tissue because the fellow cornea of the same donor was found to be normal.<sup>[9]</sup> In our case, unfortunately, there are no records that may allow us to find and evaluate the fellow cornea. Larger case series demonstrated that the recurrence is often bilateral and it may be multiple in the same patient.<sup>[4]</sup> Another hypothesis for the etiology of the recurrence is a repopulation of the graft with pathological host keratocytes that produce abnormal collagen.<sup>[1,7]</sup> On the other hand, there are genetic and environmental factors that subsist after the surgery and may play a role in the recurrence. Aging of the grafted tissue has been proposed as a causative factor as well.<sup>[2]</sup>



**Figure 4:** Corneal topography showed signs of corneal steepening in the fellow eye.

## CONCLUSION

Recurrence of KC in a corneal graft is rare. In our case, even though a pathological donor tissue could be the reason, a follow-up of the fellow eye revealed topographic corneal steepening. Therefore, the recurrence was interpreted as bilateral, as most of the case series we found in the literature. Persistence of individual and environmental factors may favor this process. However, the exact mechanism of recurrence has not been unveiled yet and further study of the physiopathology of the disease is needed.

### Declaration of patient consent

The authors certify that they have obtained all appropriate patient consent.

### Financial support and sponsorship

Nil.

### Conflicts of interest

There are no conflicts of interest.

## REFERENCES

1. Moramarco A, Gardini L, Iannetta D, Versura P, Fontana L. Post penetrating keratoplasty ectasia: Incidence, risk factors, clinical

- features, and treatment options. *J Clin Med* 2022;11:2678.
2. Abelson MB, Collin HB, Gillette TE, Dohlman CH. Recurrent keratoconus after keratoplasty. *Am J Ophthalmol* 1980;90:672-6.
3. Bourges JL, Savoldelli M, Dighiero P, Assouline M, Pouliquen Y, BenEzra D, *et al.* Recurrence of keratoconus characteristics: A clinical and histologic follow-up analysis of donor grafts. *Ophthalmology* 2003;110:1920-5.
4. Karseras AG, Ruben M. Aetiology of keratoconus. *Br J Ophthalmol* 1976;60:522-5.
5. Patel SV, Malta JB, Banitt MR, Mian SI, Sugar A, Elner VM, *et al.* Recurrent ectasia in corneal grafts and outcomes of repeat keratoplasty for keratoconus. *Br J Ophthalmol* 2009;93:191-7.
6. Lim L, Pesudovs K, Goggin M, Coster DJ. Late onset post-keratoplasty astigmatism in patients with keratoconus. *Br J Ophthalmol* 2004;88:371-6.
7. Pramanik S, Musch DC, Sutphin JE, Farjo AA. Extended long-term outcomes of penetrating keratoplasty for keratoconus. *Ophthalmology* 2006;113:1633-8.
8. Nirankari VS, Karesh J, Bastion F, Lankhanpal V, Billings E. Recurrence of keratoconus in donor cornea 22 years after successful keratoplasty. *Br J Ophthalmol* 1983;67:23-8.
9. Kremer I, Eagle RC, Rapuano CJ, Laibson PR. Histologic evidence of recurrent keratoconus seven years after keratoplasty. *Am J Ophthalmol* 1995;119:511-2.

**How to cite this article:** Lucero Saá F, Cremona FA, Chiaradia P. Recurrence of keratoconus in corneal graft. *Lat Am J Ophthalmol* 2023;6:9.