



Pictorial Essay Comprehensive

Phacoemulsification in posterior polar cataracts with a soft nucleus: Simple as ABC with proper techniques and precautions

Mansi Dinesh Devalla¹, Shubhangi S. N. Prasad¹, Balamurugan Ramatchandirane¹

¹Department of Ophthalmology, All India Institute of Medical Sciences, Guntur, Andhra Pradesh, India.



***Corresponding author:**

Balamurugan
Ramatchandirane,
Department of Ophthalmology,
All India Institute of
Medical Sciences, Guntur,
Andhra Pradesh, India.

bala16690@yahoo.co.in

Received: 31 October 2024
Accepted: 31 October 2024
Published: 06 December 2024

DOI
10.25259/LAJO_33_2024

Video available on:
https://doi.org/10.25259/LAJO_33_2024

Quick Response Code:



ABSTRACT

Posterior polar cataract (PPC) is a type of cataract characterized by opacification at the posterior pole of the lens. It poses unique challenges during surgical management due to its tendency for capsular weakness, which increases the risk of complications during phacoemulsification. If the nucleus is soft (grade <2), removal using phacoemulsification is easy after it has been delineated using hydrodelineation and viscodelineation. In this case, we aim to demonstrate and educate on the proper steps for performing phacoemulsification surgery under topical anesthesia for a 36-year-old woman who presented with PPC grade II (as per Daljit Singh classification) with a soft nucleus in her right eye.

Keywords: Posterior polar cataract, Phacoemulsification, PPC, Soft nucleus, Cataract surgery

INTRODUCTION

Posterior polar cataract (PPC) is a type of cataract characterized by opacification at the posterior pole of the lens.^[1] It poses unique challenges during surgical management due to its tendency for capsular weakness, which increases the risk of complications during phacoemulsification. Various techniques^[1-3] have been described for managing PPCs with nuclear sclerosis grades >2, including the trident technique, two-Y crushing technique, and lambda technique. However, if the nucleus is soft (grade <2),^[1] removal using phacoemulsification is easy after it has been delineated using hydrodelineation and viscodelineation. In this case, we aim to demonstrate and educate on the proper steps for performing phacoemulsification surgery under topical anesthesia [Video 1] for a 36-year-old woman who presented with PPC grade II^[2] (as per Daljit sing classification) with a soft nucleus in her right eye [Figure 1a].

Key steps for phacoemulsification in PPC with soft cataracts

Phacoemulsification settings should remain low,^[1] with ultrasound energy around 20, bottle height at approximately 70 mmHg, and vacuum levels between 150 and 200 mmHg.

1. Side Ports: Create side ports at the 10 and 2 o'clock positions using a 15-degree blade.
2. Viscoelastic Injection: Inject sodium hyaluronate 1.4% to form the anterior chamber.
3. Main Port: Create a trilamellar main port using a 2.2 mm keratome at the 11 o'clock position.
4. Capsulorhexis: Perform a continuous curvilinear capsulorhexis approximately 5mm in size

This is an open-access article distributed under the terms of the Creative Commons Attribution-Non Commercial-Share Alike 4.0 License, which allows others to remix, transform, and build upon the work non-commercially, as long as the author is credited and the new creations are licensed under the identical terms.

©2024 Published by Scientific Scholar on behalf of Latin American Journal of Ophthalmology

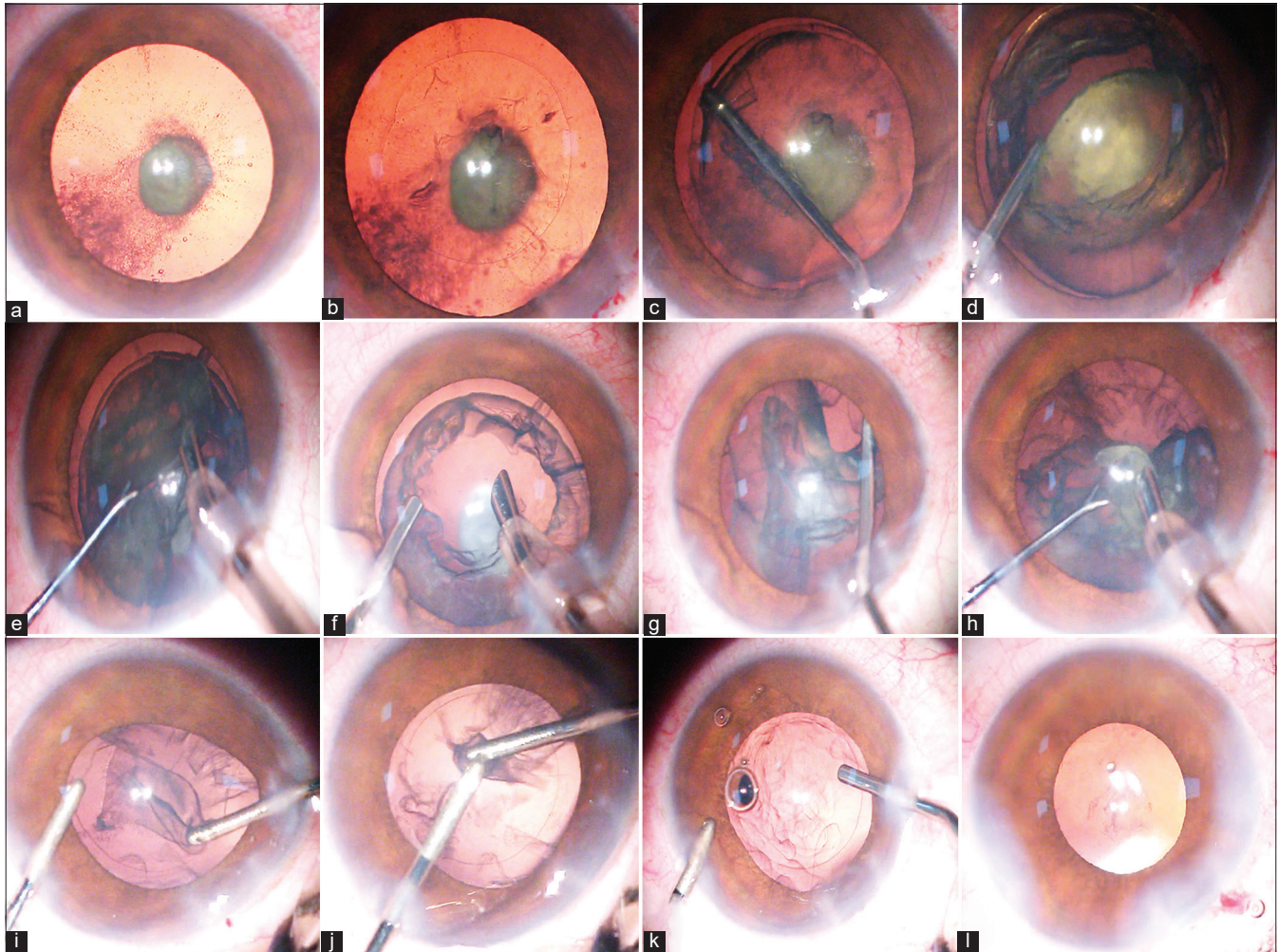


Figure 1: (a) shows the posterior polar cataract grade II with a soft nucleus. (b) shows the approximate 5 mm continuous curvilinear capsulorhexis. (c) shows hydrodelineation. (d) shows the viscodelineation to prolapse the nucleus. (e) shows the emulsification of the soft nucleus using Tilt- and-crush technique. (f) shows the injection of hydroxypropyl methyl cellulose 2% to form the anterior chamber before the removal of the irrigation source (phaco probe). (g) shows the viscodissection to separate the epinucleus from the capsule. (h) shows the removal of the epinucleus using the phaco probe. (i) shows the mechanical removal of the cortex using the aspiration probe with less vacuum and crushing it with irrigation cannula. (j) crushing the cortical matter using bimanual irrigation and aspiration cannula followed by removal using low vacuum. (k) shows the injection of the viscoelastic before removal of the irrigation cannula (irrigation source). (l) shows the implantation of the single piece intraocular lens in the bag.

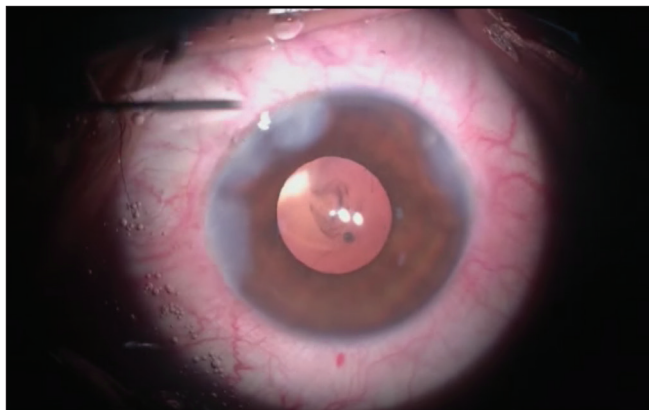
using Utrata capsulorhexis forceps [Figure 1b]. This size allows for intraocular lens (IOL) implantation in the sulcus with optic capture in case of posterior capsule rupture.^[4]

5. Hydrodelineation: Avoid hydrodissection due to the weak posterior capsule.^[1,2] Instead, perform hydrodelineation [Figure 1c] and use viscoelastic (Hydroxypropyl methyl cellulose [HPMC] 2%) to prolapse the soft nucleus (viscodelineation)^[1,2] as seen in [Figure 1d]. Once the nucleus floats on a cushion of viscoelastic, it was emulsified using the techniques for phacoemulsification in soft cataracts [Figure 1e], such as the tilt-and-crush^[5] or tilt-and-tumble methods.^[6]

6. Anterior chamber Maintenance: Ensure viscoelastic is injected before removing any irrigation source to prevent collapse of the anterior chamber [Figure 1f].

7. Epinucleus Removal: Use viscodissection^[7] to separate the epinucleus from the capsule [Figure 1g], emulsifying and removing it with the phaco probe [Figure 1h]. Form the anterior chamber with 2% HPMC before removing the phaco probe.

8. Cortex Removal: Remove the cortex [Figure 1i] using bimanual irrigation and aspiration cannulae (I&A). Instead of high vacuum, the aspiration cannula is employed to grasp cortical fibers and separate them



Video 1: Illustrates the important surgical steps of the posterior polar cataract with soft nucleus.

through a pulling action. These fibers are then crushed mechanically [Figure 1j] and aspirated. Use viscoelastic generously [Figure 1k] to maintain anterior chamber stability before removing any irrigation sources. Avoid polishing, as this may lead to rupture of the weak posterior capsule. Persistent PPC plaque should be left undisturbed; if it causes visual disturbances, it may be removed later via Nd-Yag Capsulotomy after 2 months.

9. IOL Implantation: Implant a single-piece, foldable IOL into the capsular bag [Figure 1l], and hydrate the surgical ports. Three piece IOL needs to be kept ready as it may be useful for sulcus implantation in case of posterior capsular rupture.

DISCUSSION

Phacoemulsification cataract surgery is a superior technique for managing posterior polar cataracts (PPC) compared to other methods, such as extracapsular cataract extraction (ECCE), in terms of safety¹. While various techniques for phacoemulsification in PPC have been described^{1,2}, there is currently no standard surgical approach to eliminate the primary risks associated with PPC, such as posterior capsular rupture (PCR). The risk of PCR increases when the size of the PPC exceeds 4 mm¹. When the nuclear grade is less than 2, nucleus removal or debulking is easy, as the phacoemulsification could be done within the intact posterior epinucleus after hydrodelineation. However, when the nuclear grade exceeds 2, nucleus management requires different techniques depending on the surgeon's preference and the hardness of the cataract^{1,2}. In our case, since the nucleus is soft and easily prolapsed after hydrodelineation and viscodelineation, we prefer the tilt-and-crush technique⁵ to emulsify the soft nucleus. If hydrodelineation is not occurred, the majority of the nucleus could be emulsified and removed by creating adjacent trenches to form a bowl¹, followed by viscodissection to float the remaining matter for emulsification.

CONCLUSION

This case report of a grade II PPC with a soft nucleus demonstrates the essential steps and precautions, illustrated through pictures and video. These insights can be beneficial for ophthalmologists, particularly those who are new or in training, in managing PPCs. When the correct steps are followed, managing a soft nucleus in PPC surgery is simple.

Ethical approval

Institutional Review Board approval is not required.

Declaration of patient consent

The authors certify that they have obtained all appropriate patient consent.

Financial support and sponsorship

Nil.

Conflicts of interest

There are no conflicts of interest.

Use of artificial intelligence (AI)-assisted technology for manuscript preparation

The authors confirm that there was no use of artificial intelligence (AI)-assisted technology for assisting in the writing or editing of the manuscript and no images were manipulated using AI.

REFERENCES

1. Vasavada AR, Vasavada VA. Managing the posterior polar cataract: An update. *Indian J Ophthalmol* 2017;65:1350-8.
2. Kalantan H. Posterior polar cataract: A review. *Saudi J Ophthalmol* 2012;26:41-9.
3. Ramatchandirane B, Pathuri D, Devalla MD, Sn Prasad S, Pandarasamy P. Two-Y crushing technique: A simple technique to crack the nucleus in a posterior polar cataract using two-Y rotators. *Cureus* 2024;16:e63416.
4. Mehta R, Aref AA. Intraocular lens implantation in the ciliary sulcus: Challenges and risks. *Clin Ophthalmol* 2019;13:2317-23.
5. Harb AW, Sadiq SN. Tilt-and-crush: A safe, effective and energy-saving technique for soft cataract removal. *Eur J Ophthalmol* 2020;30:1162-7.
6. Davis EA, Lindstrom RL. Tilt and tumble phacoemulsification. *Dev Ophthalmol* 2002;34:44-58.
7. Allen D, Wood C. Minimizing risk to the capsule during surgery for posterior polar cataract. *J Cataract Refract Surg* 2002;28:742-4.

How to cite this article: Devalla MD, Prasad SS, Ramatchandirane B. Phacoemulsification in posterior polar cataracts with a soft nucleus: Simple as ABC with proper techniques and precautions. *Lat Am J Ophthalmol*. 2024;7:16. doi: 10.25259/LAJO_33_2024