



## Review Article

# Traumatic macular hole: Clinical aspects and controversies

David Pelayes<sup>1</sup>, Francesc March de Ribot<sup>2,3</sup>, Ferenc Kuhn<sup>4</sup>, Sundaram Natarajan<sup>5</sup>, Wolfgang Schrader<sup>6</sup>

<sup>1</sup>Department of Ophthalmology, Universidad Maimonides, Buenos Aires, Argentina, <sup>2</sup>Department of Ophthalmology, Girona University, Catalunya, Spain, <sup>3</sup>Department of Ophthalmology, Otago University, New Zealand, <sup>4</sup>International Society of Ocular Trama, Birmingham, AL, USA, <sup>5</sup>Department of Ophthalmology, Aditya Jyot Eye Hospital Pvt. Ltd., Mumbai, Maharashtra, India, <sup>6</sup>Department of Ophthalmology, Augenabteilung Rotkreuzklinik, Augenzentrum Wuerzburg, Wuerzburg, Germany.



### \*Corresponding author:

David Pelayes. Department of Ophthalmology, Universidad Maimonides, Hidalgo 775, C1405 CABA, Argentina.

davidpelayes@gmail.com

Received : 13 July 19  
Accepted : 08 February 20  
Published : 01 April 20

DOI  
10.25259/LAJO\_16\_2019

### Quick Response Code:



## ABSTRACT

The traumatic macular hole is a rare pathology posterior to eye injuries, resulting in loss of visual acuity. It generally affects young men. The pathogenesis of macular hole formation after blunt trauma is today controversial. They frequently appear immediately after the injury, nevertheless in some cases can occur weeks later. The vision usually ranges between 20/80 and 20/400. The exploration typically shows a full-thickness defect of the neurosensory retina at the fovea, elliptical, and with irregular edges. The management can include observation under certain conditions because there is a chance of spontaneous closure. Surgery with vitrectomy obtains the closure of the hole in between 92% and 96% of cases.

**Keywords:** Traumatic macular hole, Vitrectomy, Retina, Macular hole

## INTRODUCTION

Ocular blunt trauma, among multiple injuries, may cause the macular hole, resulting in loss of vision. The first description was made by Knapp,<sup>[1]</sup> in 1869, in a young patient who suffered an eye traumatism. Noyes,<sup>[2]</sup> 2 years later, ophthalmoscopically recognized the lesion as a complete thickness defect in the center of the macula and postulated as a cause of its formation the mechanical energy created by the movement in waves of the vitreous fluid originated by the effect of blow and blow of blunt trauma. Fuchs<sup>[3]</sup> and Coats,<sup>[4]</sup> in 1901, made the first histopathological description of the lesion, noting the presence of intraretinal cysts that could form the macular hole when coalescing. Schepens, in 1955, postulated the role of the prefoveal vitreous cortex in the genesis of the defect.

## EPIDEMIOLOGY

The incidence of the traumatic macular hole varies in the literature between 1% and 9%.<sup>[5,6]</sup> Patients are generally young between the second and third decades of life and more often, male [Table 1].<sup>[7-13]</sup>

The traumatic macular hole is produced mainly by blunt ocular traumatism, being originated by balls in general of a small diameter such as tennis, squash, and handball. Other less frequent causes are blows with kicks or fists.<sup>[14]</sup> Moreover, we have to mention traumatism produced by industrial laser<sup>[15]</sup> or iatrogenically by the use of high energies in the application of Nd:YAG

This is an open-access article distributed under the terms of the Creative Commons Attribution-Non Commercial-Share Alike 4.0 License, which allows others to remix, tweak, and build upon the work non-commercially, as long as the author is credited and the new creations are licensed under the identical terms.

©2020 Published by Scientific Scholar on behalf of Latin American Journal of Ophthalmology

laser.<sup>[16]</sup> The production of a macular hole due to penetrating or perforating trauma is exceptional.

### PHYSIOLOGY

The pathogenesis of macular hole formation after blunt trauma is today controversial. They generally appear immediately after the injury, nevertheless in some cases can occur weeks later.

The main hypotheses considered are as follows:

1. The resulting retinal stretch, either from the deformation of the eyeball or the force of the impact on the pole posterior to the moment of the trauma, could cause the macular rupture<sup>[12]</sup>
2. The cystic macular degeneration due to direct injury would generate in later time the formation of the hole
3. The detachment of the posterior vitreous due to trauma could cause macular dehiscence.

Gass<sup>[17]</sup> proposes that the mechanisms by which the blunt trauma causes the macular hole can be one or the combination of:

1. Necrosis and post-contusional cystoid degeneration
2. Subfoveal hemorrhage caused by a choroidal rupture
3. Anterior-posterior vitreous traction.

We must consider the different genesis in cases of macular holes produced iatrogenically by the application of Nd:YAG laser with high energies that have a different pathogenesis. It is postulated that the Nd:YAG laser produces a thermomechanical disruption. After the application, a rapid expansion of plasma that produces cavitation in the form of a bubble immediately begins with the shock wave, leading to the dissolution of the retinal tissue with the consequent formation of the macular hole.<sup>[12,13]</sup>

### CLINICAL ASPECTS

Patients with a traumatic macular hole present a vision that commonly ranges between 20/80 and 20/400. Biomicroscopy

of the posterior segment typically shows a full-thickness defect of the neurosensory retina at the fovea, usually elliptical and with irregular edges as opposed to idiopathic macular holes, which is generally round in shape and regular edges.<sup>[14]</sup> They present an average size of between 0.2 and 0.5 diameters of the optic disc. In 5% of cases, we can see a free operculum and in 10% a retinal detachment around the hole. The posterior vitreous remains completely adhered in 85% of the cases, partially adhered in 15%, it is rare to find a total posterior vitreous detachment.<sup>[12]</sup> We can observe yellowish deposits at the base of the hole. The finding of an epiretinal membrane is infrequent [Figure 1a], which, if present, is late onset.<sup>[18]</sup>

When dealing with blunt ocular trauma of a complex entity, we can often find the following associations in both the anterior and/or posterior segments: Vitreous hemorrhage, hyphema, chorioretinal atrophy, choroidal ruptures, angular recessions, retinal tears, retinal dialysis, and retinal detachment [Figure 1b].

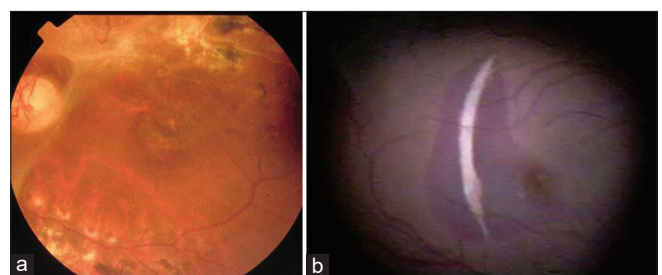
### COMPLEMENTARY EXAMINATIONS

Principally, two complementary tests are used to help in the diagnosis of traumatic macular hole: Retinal fluorescein angiography and optical coherence tomography (OCT).

The retinal fluorescein angiography typically shows a central hyperfluorescence by window effect corresponding to the base of the macular hole, a hyperfluorescence around the hole corresponding to subretinal fluid, you can also find deposits at the base of the hole that is hypofluorescent [Figures 2 and 3].

The OCT shows complete retinal thickness loss at the foveal level with an abrupt slope between the steep edges of the hole and the pigmentary epithelium; the presence of operculum; cystic retinal changes; presence of an epiretinal membrane; and presence of abnormalities in the surrounding retina [Figure 4a and b].<sup>[19]</sup> OCT is currently an essential study.

Author	Number of treated eyes	Average age	Age range	% male/female
Amari <i>et al.</i> <sup>[7]</sup>	23	28	13–49	95.7/4.3
Johnson <i>et al.</i> <sup>[8]</sup>	25	23	8–36	80/20
Yamashita <i>et al.</i> <sup>[9]</sup>	8	14.6	11–21	100
Chow <i>et al.</i> <sup>[10]</sup>	16	25	7–60	56/44
García-Arumí <i>et al.</i> <sup>[11]</sup>	14	19	12–36	80/20
Yanagiya <i>et al.</i> <sup>[12]</sup>	20	24	9–54	85/15
Chen <i>et al.</i> <sup>[13]</sup>	8	39.6	12–74	87.5/12.5

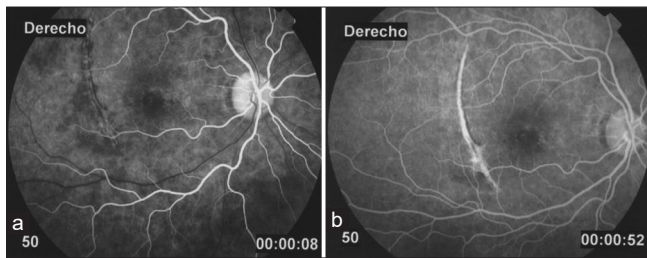


**Figure 1:** (a) Retinography presenting a traumatic macular hole and an epiretinal membrane. (b) Retinography shows choroidal rupture, subretinal hemorrhage, and a macular hole. A 20-year-old male patient presenting decreased vision in the right eye secondary to trauma with a ball.

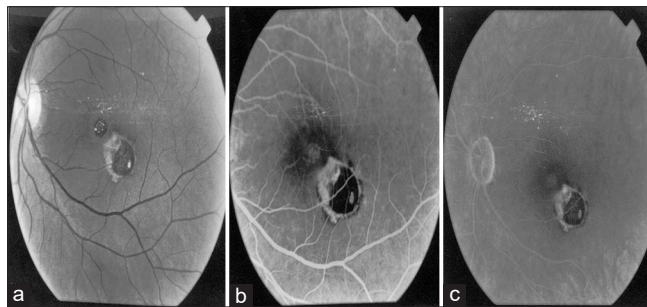
## TREATMENT

The treatment of the traumatic macular hole is controversial. On the one hand, observation can be considered because there is a chance of spontaneous closure. It has been found in cases with small diameter holes (0.1–0.2 diameters of the optic disc), without detachment of the posterior vitreous, or presence of epiretinal membrane.<sup>[5,20-22]</sup> The spontaneous closure has been described in some series up to 40% of the cases, after 2 months or more of the injury,<sup>[5,20-24]</sup> until 66.7% after 6 months.<sup>[25]</sup>

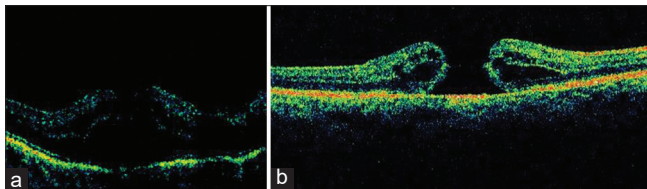
On the other hand, surgery realizing a pars plana vitrectomy has excellent closure results, with mechanical creation of a posterior vitreous detachment, expandable gas exchange C3F8 or SF6 at different concentrations, and post-operative positioning in a prone position for a period of given



**Figure 2:** (a and b) Retinal Fluorescein Angiography showing central hyperfluorescence by window effect that corresponds to the hole with a decreased signal in the edges by the subretinal liquid, and vertical arcuate hyperfluorescence corresponding to choroidal rupture.



**Figure 3:** (a-c) Retinal Fluorescein Angiography showing two traumatic macular holes in the same eye.



**Figure 4:** (a and b) Optical coherence tomography (OCT) showing a complete retinal thickness defect, intra-retinal cysts at the edges of the hole and subretinal fluid.

time.<sup>[7,8,10]</sup> The peeling of the internal limiting membrane and the extraction of the epiretinal membrane, in case of being present, are other factors to consider. The anatomical closure of the hole occurs between 92% and 96% of cases [Figure 5].<sup>[7,8,10,11,20]</sup>

Some authors describe the use of substances (transforming growth factor-beta 2, platelet concentrate, and serum) as an adjuvant to achieve hole closure.<sup>[5,10,11]</sup> It was not shown that the use of these substances improved the effectiveness of vitrectomy in terms of anatomical results as opposed to non-use [Table 2].<sup>[7,8,10,11,20]</sup>

The giant traumatic macular holes can benefit from large inverted internal limiting peeling and retinal transplantation.<sup>[26,27]</sup>

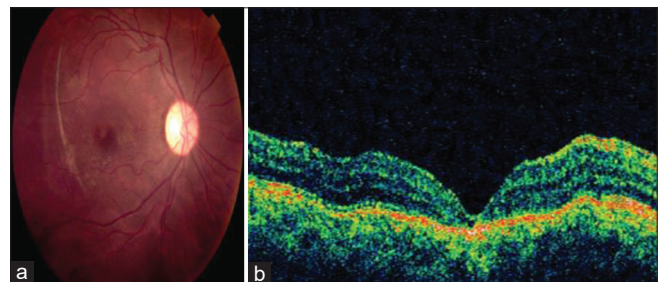
Among the complications of surgery are retinal hemorrhages, retinal detachment [Figure 6], and visual defects, cataract formation is not typical, contrary to what happens in idiopathic macular hole surgery where it is a common complication.

## PROGNOSIS

The visual acuity at presentation varies from 20/30 to 20/400, depending on the retinal affection: Retinal detachment,

**Table 2:** Treatment, anatomical results.

Author	Number of treated eyes	Surgical technique	% macular hole closure
Chow <i>et al.</i> <sup>[10]</sup>	16	Vitrectomy+C3F8 14–16%	93.75
Johnson <i>et al.</i> <sup>[8]</sup>	25	Vitrectomy+C3F8 14–16%	96
Amari <i>et al.</i> <sup>[7]</sup>	23	Vitrectomy+SF6	95.7
García-Arumí <i>et al.</i> <sup>[11]</sup>	14	Vitrectomy+platelet concentrate+SF6 25%	92.86
Rubin <i>et al.</i> <sup>[20]</sup>	12	Vitrectomy+TGF-beta 2+gas	92



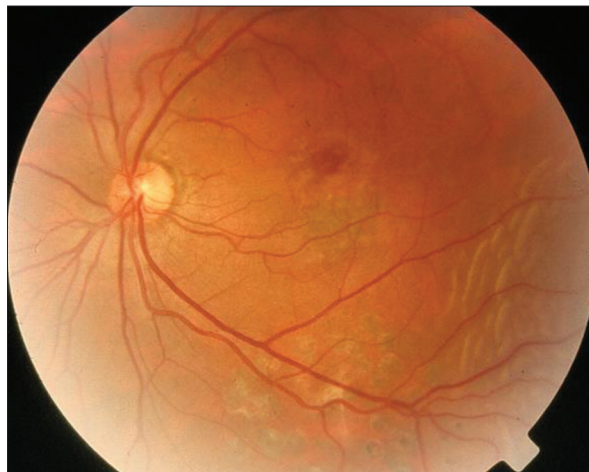**Figure 5:** (a) Post-surgical retinography showing anatomical closure of the macular hole; (b) Correlation with OCT confirming the anatomical closure.

vitreous hemorrhage, retinal hemorrhage, choroidal rupture, or retinal pigment epithelium damage.

The post-surgical prognosis is favorable. Patients experience an improvement in their visual acuity of two or more lines of vision between 69% and 93%. Almost 50% of patients present a visual acuity of 20/40 or better after surgical treatment [Table 3].<sup>[7-11]</sup>

The patients in whom the spontaneous closure of the hole occurred followed the same evolution of their visual acuity as those treated by surgery.<sup>[24,28]</sup>

The time interval from injury to surgery was statistically associated significantly with the level of visual acuity improvement.<sup>[24,28]</sup> The different tomographic macular hole presentations has not shown a clear prognosis relation,<sup>[25,29]</sup> but cystic edema on the edge of the hole may be an unfavorable factor for the spontaneous closure of TMH.<sup>[25]</sup>



**Figure 6:** Retinography showing a post-surgical traumatic macular hole presenting as a complication a retinal detachment.

**Table 3:** Functional results.

Author	Onset visual acuity range	% best-corrected visual acuity	% visual acuity improvement more than two lines
Johnson <i>et al.</i> <sup>[8]</sup>	20/70–20/250	64% 20/50 or more	84
Chow <i>et al.</i> <sup>[10]</sup>	20/80–counting fingers	38% 20/40 or more	69
García-Arumí <i>et al.</i> <sup>[11]</sup>	20/50–20/400	50% 20/30 or more	93
Amari <i>et al.</i> <sup>[7]</sup>	20/40–20/1000	48% 20/40 or more	87
Yamashita <i>et al.</i> <sup>[9]</sup>	20/60–20/2000	50% 20/40 or more	8

## CONCLUSIONS

The traumatic macular hole is a rare pathology; its pathogenesis is currently controversial. The OCT is the auxiliary diagnostic method most used for its high resolution and innocuousness for the patient. The most widely used treatment is vitrectomy with an expandable liquid–gas exchange. Nevertheless, observation can be considered in patients  $\leq 24$  years of age with macular hole sizes of  $\leq 0.2$  optic disc diameter, without detachment of the posterior vitreous or epiretinal membrane, because they are more likely to achieve spontaneous closure of the hole.

### Declaration of patient consent

Patient’s consent not required as patients identity is not disclosed or compromised.

### Financial support and sponsorship

Nil.

### Conflicts of interest

There are no conflicts of interest.

## REFERENCES

- Knapp H. Ueber isolirte zerreissungen der aderhaut infolge von traumen auf augapel. Arch Augenheilkd 1869;1:6-29.
- Noyes HD. Detachment of retina with laceration at macula. Trans Am Ophthalmol Soc 1871;1:128-9.
- Fuchs E. Zur veränderung der macula lutea nach contusion. Z Augenheilkd 1901;6:181-6.
- Coats G. The pathology of macular holes. Roy Lond Hosp Rep 1907;17:69.
- Margheria RR, Schepens CL. Macular breaks. 1. Diagnosis, etiology, and observations. Am J Ophthalmol 1972;74:219-32.
- Aaberg TM. Macular holes: A review. Surveill Ophthalmol 1970;15:139-62.
- Amari F, Ogino N, Matsumura M, Negi A, Yoshimura N. Vitreous surgery for traumatic macular holes. Retina 1999;19:410-3.
- Johnson RN, McDonald HR, Lewis H, Grand MG, Murray TG, Mieler WE, *et al.* Traumatic macular hole: Observations, pathogenesis, and results of vitrectomy surgery. Ophthalmology 2001;108:853-7.
- Yamashita T, Uemara A, Uchino E, Doi N, Ohba N. Spontaneous closure of traumatic macular hole. Am J Ophthalmol 2002;133:230-5.
- Chow DR, Williams GA, Trese MT, Margherio RR, Ruby AJ, Ferrone PJ. Successful closure of traumatic macular holes. Retina 1999;19:405-9.
- García-Arumí J, Corcostegui B, Cavero L, Sararols L. The role of vitreoretinal surgery in the treatment of posttraumatic macular hole. Retina 1997;17:372-7.
- Yanagiya N, Akiba J, Takahashi M, Shimizu A, Kakehashi A,

- Kado M, *et al.* Clinical characteristics of traumatic macular holes. *Jpn J Ophthalmol* 1996;40:544-7.
13. Chen YP, Chen TL, Chao AN, Wu WC, Lai CC. Surgical management of traumatic macular hole-related retinal detachment. *Am J Ophthalmol* 2005;140:331-3.
  14. Yokotsuka K, Kishi S, Tobe K, Kamei Y. Clinical features of traumatic macular hole. *Jpn J Clin Ophthalmol Rinsho Ganka* 1991;45:1121-4.
  15. Bourgeois H, Maurin JF, Auduge A, Ocamica P, Lucas B, Mir F, *et al.* Ocular damage caused by industrial lasers. Apropos of 3 accidents. *Ophthalmologie* 1989;3:225-6.
  16. Sou R, Kusaka S, Ohji M, Gomi F, Ikuno Y, Tano Y. Optical coherence tomographic evaluation of a surgically treated traumatic macular hole secondary to Nd: YAG laser injury. *Am J Ophthalmol* 2003;135:537-9.
  17. Gass JD. *Stereoscopic Atlas of Macular Diseases: Diagnosis and Treatment*. 4<sup>th</sup>ed., Vol. 2. St. Louis: Mosby; 1997. p. 744.
  18. Gill M, Lou P, Ray S, Jakobiec F. Ocular trauma: Traumatic macular holes. *Int Ophthalmol Clin* 2002;3:97-106.
  19. Arevalo JF, Sanchez JG, Costa RA, Farah ME, Berrocal MH, Graue-Wiechers F, *et al.* Optical coherence tomography characteristics of full-thickness traumatic macular holes. *Eye (Lond)* 2008;22:1436-41.
  20. Rubin JS, Glaser BM, Thompson JT, Sjaarda RN, Pappas SS, Murphy RP. Vitrectomy, fluid-gas exchange and transforming growth factor--beta-2 for the treatment of traumatic macular holes. *Ophthalmology* 1995;102:1840-5.
  21. Mitamura Y, Wataru S, Masahiro I, Yamamoto S, Takeuchi S. Spontaneous closure of traumatic macular hole. *Retina* 2001;21:385-9.
  22. Yamada H, Sakai A, Yamada E, Nishimura T, Matsumura M. Spontaneous closure of traumatic macular hole. *Am J Ophthalmol* 2002;134:340-7.
  23. Kusaka S, Fujikado T, Ikeda T, Tano Y. Spontaneous disappearance of traumatic macular holes in young patients. *Am J Ophthalmol* 1997;123:837-9.
  24. Gao M, Liu K, Lin Q, Liu H. Management modalities for traumatic macular hole: A systematic review and single-arm meta-analysis. *Curr Eye Res* 2017;42:287-96.
  25. Chen HJ, Jin Y, Shen LJ, Wang Y, Li ZY, Fang XY, *et al.* Traumatic macular hole study: A multicenter comparative study between immediate vitrectomy and six-month observation for spontaneous closure. *Ann Transl Med* 2019;7:726.
  26. Özkan B, Karabaş VL. Surgical closure of giant traumatic macular hole with retinal graft. *Eur J Ophthalmol* 2019;29:NP14-7.
  27. Singh SR, Narayanan R. Functional and morphological evaluation of autologous retinal graft in large traumatic macular hole. *Indian J Ophthalmol* 2019;67:1760-2.
  28. Miller JB, Yonekawa Y, Elliott D, Kim IK, Kim LA, Loewenstein JJ, *et al.* Long-term follow-up and outcomes in traumatic macular holes. *Am J Ophthalmol* 2015;160:1255-80.
  29. Huang J, Liu X, Wu Z, Lin X, Li M, Dustin L, *et al.* Classification of full-thickness traumatic macular holes by optical coherence tomography. *Retina* 2009;29:340-8.

**How to cite this article:** Pelayes D, March de Ribot F, Kuhn F, Natarajan S, Schrader W. Traumatic macular hole: Clinical aspects and controversies. *Lat Am J Ophthalmol* 2020;3:3.