



Case Report Retina

Spontaneous release of epiretinal membrane in a patient with a retinal vasoproliferative tumor

Daniel Cortes-Muñoz¹ , Alan Chew-Bonilla¹ , Carlos Illescas-Lomeli² , Rene Alfredo Cano-Hidalgo¹

Departments of ¹Retina and Vitreous a, ²Ophthalmology, Instituto de Oftalmología Conde de Valenciana, Mexico City, Mexico.



*Corresponding author:

Rene Alfredo Cano-Hidalgo,
Department of Retina
and Vitreous, Instituto de
Oftalmología Conde de
Valenciana, Mexico City,
Mexico.

drre necano@yahoo.com.mx

Received : 13 April 2023

Accepted : 19 April 2023

Published : 10 May 2023

DOI

10.25259/LAJO_9_2023

Quick Response Code:



ABSTRACT

A 36-year-old woman was scheduled for a vitrectomy of her left eye due to an epiretinal membrane (ERM) secondary to a retinal vasoproliferative tumor. Visual acuity (VA) was 20/20 in the right eye and 20/80 in the left. Before surgery, the patient's vision had improved (20/20). Fundus examination and tomographic images revealed the spontaneous release of the ERM. ERM release usually presents after cryotherapy and photocoagulation. This is the first case in the literature documenting spontaneous ERM release in a vasoproliferative tumor.

Keywords: Retinal vasoproliferative tumor, Epiretinal membrane, Spontaneous release

INTRODUCTION

Retinal vasoproliferative tumors (RVPTs) present as rare retinal lesions, which can be primary and idiopathic (74% of cases) or secondary to other ocular diseases (26% of cases), such as inflammatory and traumatic.^[1] They usually manifest at age 20–40, without any sex or ethnicity predisposition. On examination, RVPT is a retinopathy that appears as a pink to yellow raised mass with tortuous vessels within, located in the pre-equatorial inferior temporal quadrant of the retina.^[2] Visual acuity can be compromised by macular fibrosis, epiretinal membrane formation, cystoid macular edema, and subretinal fluid. Histological examination has proven that the RVPTs are a vascularized proliferation of glial and astrocytic components, not neoplasia.^[3] Treatment depends on VA, symptoms, tumor size and location, and ocular complications. RVPTs can be managed with periodical observation, transconjunctival cryotherapy, brachytherapy, photocoagulation, and even vitrectomy if ERM has macular involvement and is causing visual impairment.^[4] Spontaneous release of ERM has been reported in idiopathic ERM, but not in RVPT and it might be due to vitreous traction or membrane contraction.^[5,6]

CASE REPORT

In this case, we described the case of a 39-year-old female with a 5-month history of metamorphopsia and visual impairment (VA of 20/80) of her left eye. Fundus examination showed classic findings of an epiretinal membrane and an added red-dome-shaped mass at the peripheral retina of 4 mm (about 0.16 inch) thickness corresponding to a primary vasoproliferative tumor [Figure 1a and b].

This is an open-access article distributed under the terms of the Creative Commons Attribution-Non Commercial-Share Alike 4.0 License, which allows others to remix, transform, and build upon the work non-commercially, as long as the author is credited and the new creations are licensed under the identical terms.

©2023 Published by Scientific Scholar on behalf of Latin American Journal of Ophthalmology

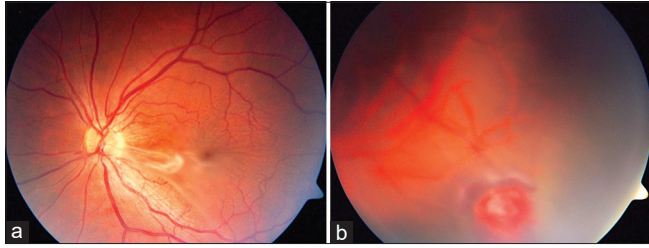


Figure 1: A 36-year-old female with primary vasoproliferative tumor. (a) Fundus photography shows an epiretinal membrane causing macular distortion. (b) Fundus photograph showing a red mass in the inferotemporal periphery. Associated telangiectasia can be seen on the surface of the tumor.

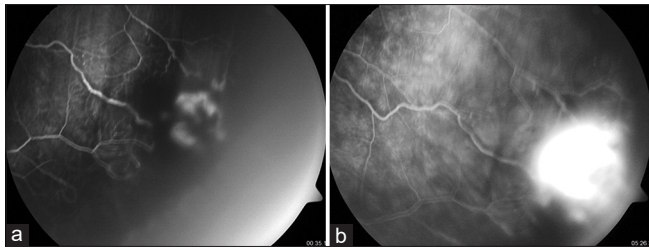


Figure 2: Fluorescein angiography images. (a) The early phase shows hyperfluorescence within the mass corresponding with the capillary vascular network. (b) Massive hyperfluorescence lesion due to leakage in the late phase.

We performed multimodal imaging; OCT revealed distortion of the internal and external layers of the retina with macular thickening because of the ERM traction. Fluorescein angiography imaging showed significant hyperfluorescent staining in early phases with late leakage [Figure 2a and b].

Due to the visual impairment and symptoms, the patient was scheduled for vitrectomy and epiretinal membrane removal. Nevertheless, 2 days before surgical intervention, the patient improved her visual acuity (VA of 20/20) and had metamorphopsia cessation of her left eye. Fundus examination revealed the spontaneous release of the ERM [Figure 3]. In addition, tomographic images showed the release of the ERM and the restoration of the anatomical structure of the macula with adequate thickness [Figure 4].

ERM is a cause of visual impairment in RVPTs, representing a common complication with a cumulative risk of 19.5% in 2 years. Surgical removal of the ERM is indicated when patients are symptomatic and visually impaired. Alternative treatments are cryotherapy, photocoagulation, and intravitreal bevacizumab injection since they cause ERM detachment afterward. The authors report an ERM to release within a year in 63% of cases in tumors with 6 mm size and 3 mm thickness treated with cryotherapy.^[7] Furthermore, photocoagulation has shown the release 1–8 months after treatment in other pathologies.^[8,9] ERM detachment might be

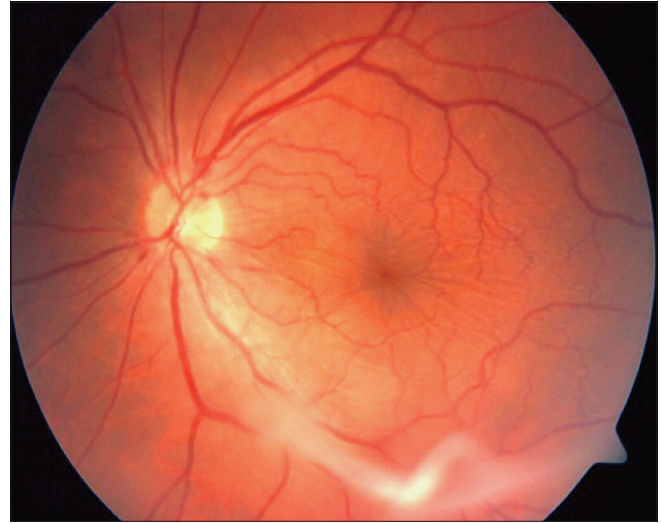


Figure 3: Fundus photography shows the epiretinal membrane detached.

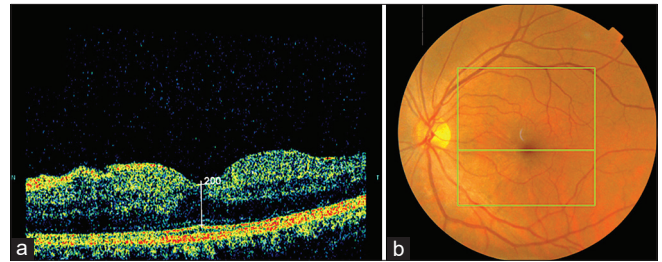


Figure 4: Follow-up optical coherence tomography at 2 weeks showing no epiretinal membrane and no macular distortion.

due to an accelerated posterior vitreous detachment because of the heat and inflammation caused by the laser.^[9]

To the best of our knowledge, this is the first case in the literature documenting spontaneous epiretinal membrane in a RVPT. On the other hand, spontaneous release of epiretinal membranes has been reported in capillary hemangioma, Leber's multiple miliary aneurysms, coats disease, combined hamartoma of the retina and retinal pigment epithelium, and toxoplasma retinochoroiditis.^[10]

CONCLUSION

The clinical evolution and prognosis in RVPTs vary widely and depend on the related ocular diseases and associated complications. The treatment has not been established and is based on close observation and control of the complications, in cases even seeing spontaneous improvement, as presented in this case.

Declaration of patient consent

The authors certify that they have obtained all appropriate patient consent.

Financial support and sponsorship

Nil.

Conflicts of interest

There are no conflicts of interest.

REFERENCES

1. Heimann H, Bornfeld N, Vij O, Coupland S, Bechrakis N, Kellner U, *et al.* Vasoproliferative tumours of the retina. *Br J Ophthalmol* 2000;84:1162-9.
2. Shields CL, Kaliki S, Al-Dahmash S, Rojanaporn D, Shukla SY, Reilly B, *et al.* Retinal vasoproliferative tumors: Comparative clinical features of primary vs secondary tumors in 334 cases. *JAMA Ophthalmol* 2013;131:328-34.
3. Perry LJ, Jakobiec FA, Zakka FR, Reichel E, Herwig MC, Perry A, *et al.* Reactive retinal astrocytic tumors (so-called vasoproliferative tumors): Histopathologic, immunohistochemical, and genetic studies of four cases. *Am J Ophthalmol* 2013;155:593.
4. Smith J, Steel D. The surgical management of vasoproliferative tumours. *Ophthalmologica* 2011;226 Suppl 1:42-5.
5. Menteş J, Nalçacı S. An unusual case: Self-separation of an idiopathic epiretinal membrane. *Turk J Ophthalmol* 2020;50:56-8.
6. Kida T, Morishita S, Fukumoto M, Sato T, Oku H, Ikeda T. Long-term evaluation of spontaneous release of epiretinal membrane and its possible pathogenesis. *Clin Ophthalmol* 2017;11:1607-10.
7. Manjandavida FP, Shields CL, Kaliki S, Shields JA. Cryotherapy-induced release of epiretinal membrane associated with retinal vasoproliferative tumor: Analysis of 16 cases. *Retina* 2014;34:1644-50.
8. Imasawa M, Iijima H. Release of vitreomacular traction following retinal photocoagulation in an eye with branch retinal vein occlusion. *Int Ophthalmol* 2009;29:63-5.
9. Kolomeyer AM, Eller AW, Martel JN. Spontaneous resolution of macular epiretinal membranes after fluorescein potentiated argon laser treatment of von hippel-lindau associated retinal hemangiomas: Case report and review of literature. *Retin Cases Brief Rep* 2016;10:145-50.
10. Sugimoto M, Sasoh M, Ito Y, Miyamura M, Uji Y, Chujo S. A case of Coats' disease with a peeling of premacular fibrosis after photocoagulation. *Acta Ophthalmol Scand* 2002;80:96-7.

How to cite this article: Cortes-Muñoz D, Chew-Bonilla A, Illescas-Lomeli C, Cano-Hidalgo RA. Spontaneous release of epiretinal membrane in a patient with a retinal vasoproliferative tumor. *Lat Am J Ophthalmol* 2023;6:7.